
Treatment of an Extremely Atrophic Maxilla with Sinus Lift and Simultaneous Placement of a Trabecular Metal™ Dental Implant: A Case Report

Carlo Maria Soardi, MD, DDS. Private practice, Brescia, Italy and Hom-Lay Wang, DDS, MSD, PhD. Collegiate Professor of Periodontology, Professor of Dentistry and Director of Graduate Periodontics, University of Michigan School of Dentistry, Ann Arbor, MI.

INTRODUCTION

In modern implant surgery, it is well known that implant restoration of the upper maxilla is less favorable than the mandible. This is because maxillary bone is less abundant and of lower density than bone in the premaxilla or mandible. The posterior area of the upper jaw has anatomical features that make it unique compared to other areas, mainly due to the presence of the maxillary sinus.¹

After tooth loss there is progressive bone resorption, combined with sinus pneumatization and loss of bone height and quality, which can complicate the placement of dental implants.²

An essential condition for success in dental implant treatment is to ensure that the required quantity and quality of bone is present in the area where, after careful diagnosis and planning, placement of dental implants would be most beneficial to the patient. Certain clinicians³ report that, of the 2.1% overall failure rate of dental implants, 41% tend to be in patients with a minimal bone height (1-2 mm) in the posterior maxilla where the relationship between reduced bone-to-implant contact (BIC) and dental implant failure is quite evident. It is also known that a textured surface implant may help to improve the outcome.⁴

To increase BIC, and in contrast to conventional BIC achieved by non-porous surfaces, we chose to use a new dental implant (*Trabecular Metal* Dental Implant, Zimmer Dental Inc., Carlsbad, CA, USA) (TM Dental Implant) that features a midsection designed to be structurally similar to cancellous bone. The geometrical tantalum network of interconnected pores allows bone ingrowth and ongrowth (osseoincorporation), which is designed to make the system more stable, especially in soft bone.

The aim of this article is to describe the placement of a TM Dental Implant in soft bone and graft material during sinus lift surgery.

CASE REPORT

A 52-year-old man presented for implant and crown restoration due to the loss of a right maxillary first molar. A review of the patient's clinical history indicated that he was in good health with no history of smoking, drugs or illness. Intraoral examination and imaging were performed to plan the surgery. Clinical examination revealed healthy,

keratinized mucosa with no evidence of infection (Figs. 1-2). There was a distal pocket on the maxillary right 2nd premolar (8mm probing) with gingival recession that extended to the adjacent 1st premolar.

Panoramic radiography (Fig. 3) and cone beam computer tomography (Planmeca Romexis®) (CBCT) showed a minimal bone height remaining (3 mm), and a distance of 4 mm from the crestal bone to the cemento-enamel joint (CEJ), which was a class C-v recession according to Wang and Katranji (Fig. 4).⁵ Due to the gingival recession of both premolars, the periodontal pocket around the 2nd premolar, and the patient's occlusion, a one-stage sinus lift procedure was performed using a lateral window technique, followed by immediate placement of a TM Dental Implant in the maxillary right 1st molar area after sinus bone grafting.

CLINICAL REPORT

After local injection with articain hydrochloride (Ultracaine®, Sanofi-Aventis, Deutschland GmbH, Frankfurt, Germany) to induce anesthesia, a full-thickness flap was retracted to expose the lateral wall of the maxillary sinus (Fig. 5). A bony window osteotomy was performed according to Vercellotti et al.⁶ using a piezosurgery device (Mectron® S.p.a., Carasco, Genova, Italy) (Figs. 6-7). The hinged bony window was fractured inward (Fig. 8) and lifted upward (Figs. 9-10) without removal from the hinged portion of the window, and the Schneiderian membrane was gently elevated using a piezosurgical device and a broad curette. A collagen membrane (*BioMend*®, Zimmer Dental Inc.) was shaped to the concavity of the sinus surface, placed into the maxillary sinus and pressed against the Schneiderian membrane (Figs. 11-12).⁷ An 80% cortical and 20% cancellous bone allograft material (*Puros*®, Zimmer Dental Inc., Carlsbad, CA, USA) was mixed with saline solution, put into the sinus cavity and gently packed beneath the elevated bony window, Schneiderian membrane and the residual sinus floor.⁸ The implant site was prepared by sequential drilling at 1200 rpm.

To determine the length of the dental implant, a buttoned probe was inserted into the osteotomy while taking care not to apply stress to the elevated Schneiderian membrane (Fig. 13). The selected TM Dental Implant (4.7 x 11.5) (Fig. 14) was placed in the osteotomy with a torque lower than 30

Figure 1

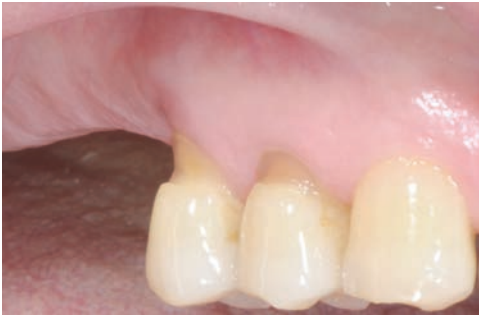

Figure 2

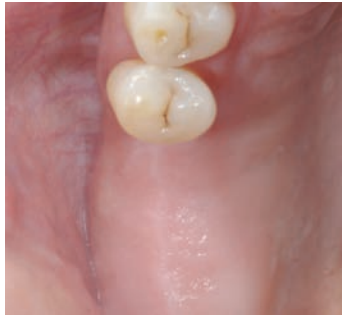

Figure 3

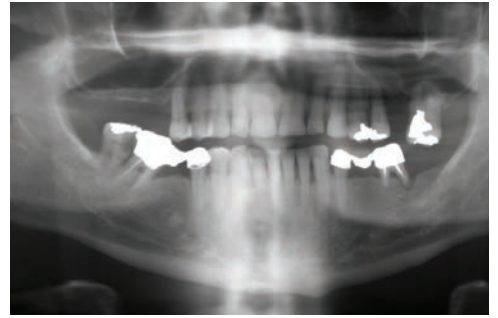


Figure 4

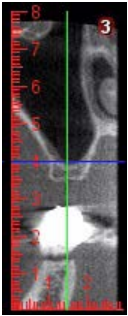


Figure 5

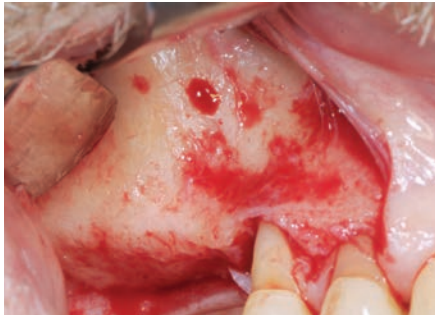

Figure 6

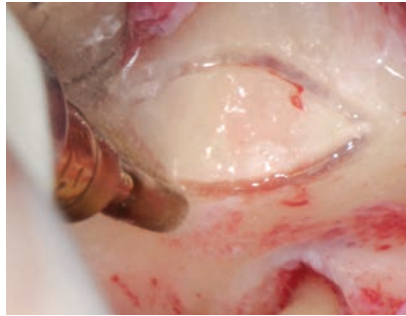


Figure 7

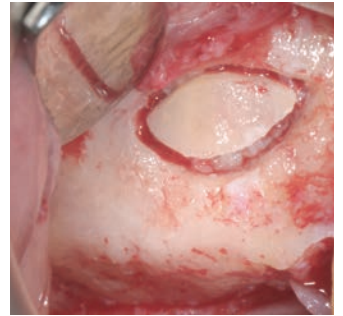


Figure 8

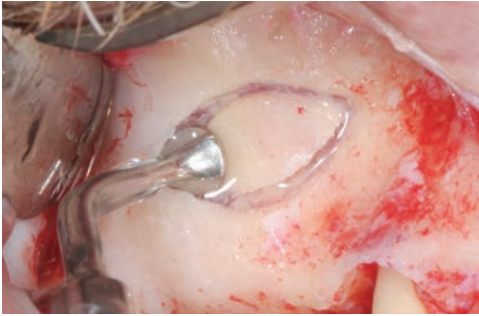


Figure 9

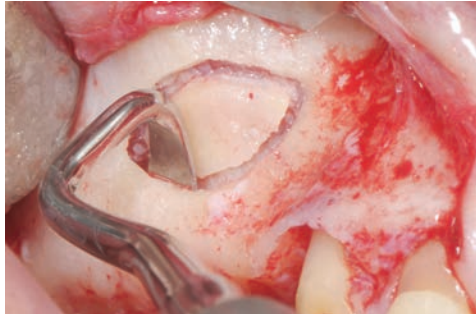


Figure 10

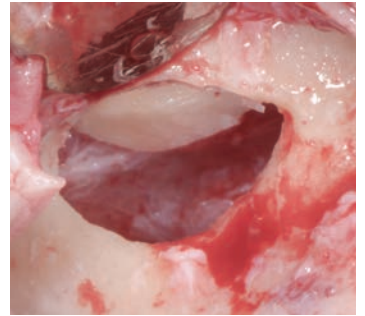


Figure 11

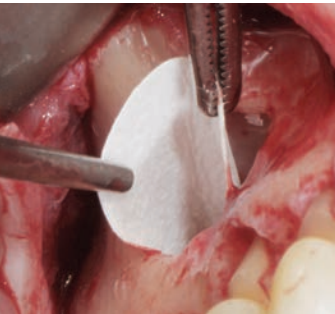


Figure 12

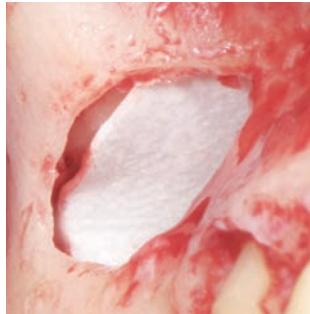


Figure 13

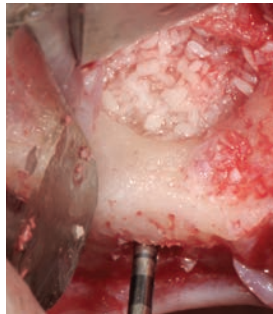


Figure 14



Figure 15

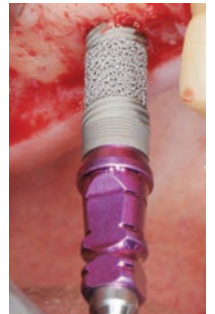

Figure 16



Figure 17

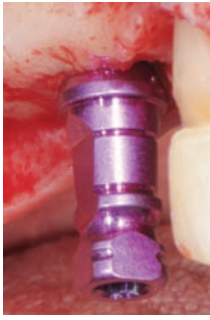

Figure 18

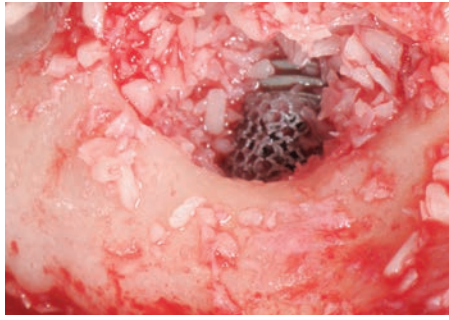


Figure 19

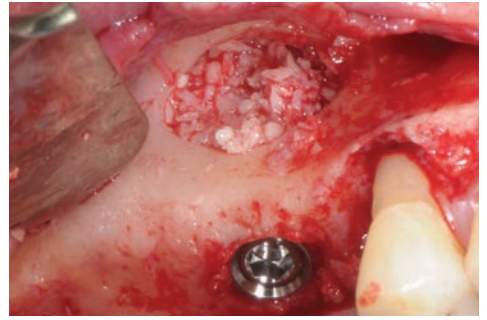


Figure 20

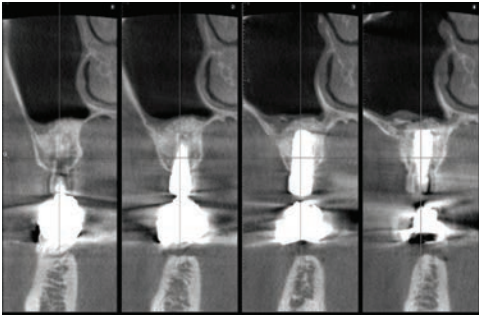


Figure 21

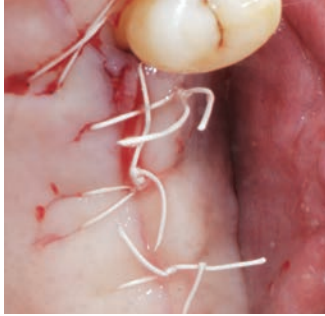


Figure 22

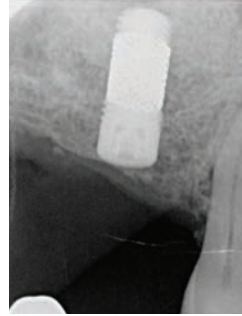


Figure 23

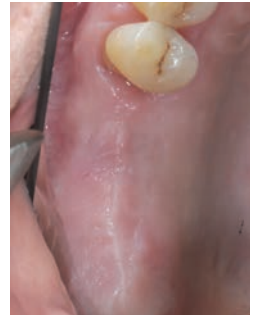

Figure 24

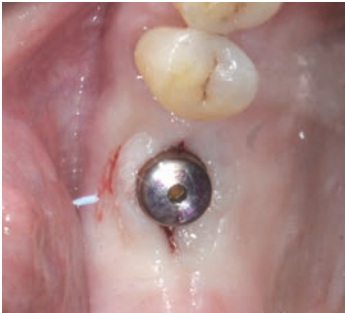

Figure 25

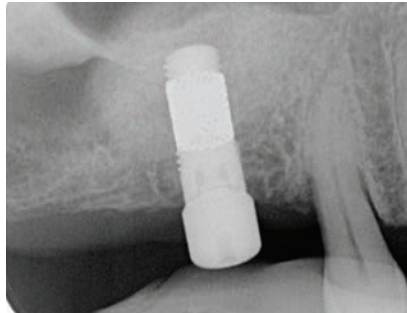

Figure 26

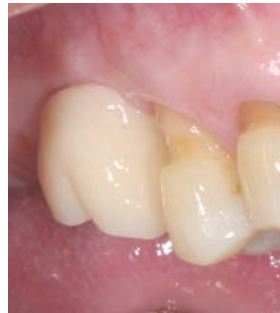
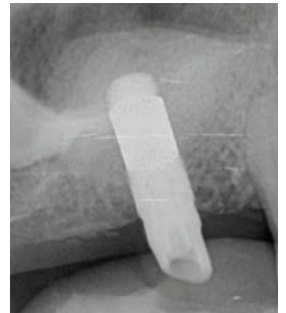
Figure 27



Ncm (Figs. 15-17) using an osteocompressive (soft bone)⁹ surgical technique. During placement, the bone allograft was slightly compacted and the *Trabecular Metal Material* portion of the dental implant became exposed through the lateral window of the maxillary wall (Fig. 18). Additional bone allograft material was packed over the visible tantalum to close the sinus lateral window (Figs. 18-19). The vestibular flap was repositioned and sutured (Gore-Tex[®] 5/0, W.L. Gore&Associates, Flagstaff, AZ, USA) (Fig. 21).

A CBCT scan was performed after surgery to establish a baseline for the implant position and the bone graft¹⁴ (Fig. 20). The patient was educated in the home use of Clorexidine 0.12% mouthwash twice a day and no brushing

of the surgical site for two weeks, and then was discharged with prophylactic antibiotics (Amoxicillin 1g twice a day for 7 days) and analgesics (Naproxen sodium 550 mg if swelling or pain). Sutures were removed 14 days after surgery. Every month the patient was checked for possible wound dehiscence or any other complications that would require immediate treatment.

Imaging was performed at implant placement (Figs. 22-23) and the surgical uncovering 6 months after placement (Figs. 24-25). At that time a temporary restoration was placed. Nine months after application of the temporary crown, no crestal bone level changes were observed (Figs. 26-27).

RESULTS

After loading, the TM Dental Implant remained stable in the regenerated bone. No problems were recorded and no peri-implant bone loss was observed radiographically 15 months after surgery.

DISCUSSION

Lack of bone volume and soft bone often make implant restoration in the maxillary jaw more difficult than in the mandible or premaxilla. There is a very close relationship between low bone density, BIC and less favorable dental implant prognosis.^{8,10-11} Under these conditions, the 3-dimensional porous design of TM Dental Implants may enhance secondary stability through the osseoincorporation process.¹²⁻¹³ When a TM Dental Implant is placed, blood vessels can easily invade the pores of the trabecular structure. This condition allows the bone not only to grow into the pores, but may also enable the formation of interconnected trabeculae.¹⁴ This three dimensional bone structure, combined with the friction-fit abutment connection, are designed for a stable implant restoration.

Although individual case report has no statistical significance, it provides fundamental clinical information that may benefit other clinicians and suggest areas for more extensive research. To that end, the author hopes that additional studies with a greater number of surgical cases treated with TM Dental Implants will confirm the findings of this case report.

REFERENCES

1. Raja SV. Management of the posterior maxilla with sinus lift: review of techniques. *J Oral Maxillofac Surg.* 2009;67:1730-4.
2. Garg AK. Augmentation grafting of the maxillary sinus for placement of dental implants: anatomy, physiology and procedures. *Implant Dent.* 1999;8:36-46.
3. Peleg M, Garg AK, Mazor Z. Predictability of simultaneous implant placement in the severely atrophic posterior maxilla: A 9-year longitudinal experience study of 2132 implants placed into 731 human sinus grafts *Int J Oral Maxillofac Implants.* 2006;21:94-102.
4. Shalabi MM, Gortemaker A, Van't Hof MA, Jansen JA, Creugers NH. Implant surface roughness and bone healing: a systematic review. *J Dent Res.* 2006 Jun;85(6):496-500.
5. Wang HL, Katranji A. ABC sinus augmentation classification. *Int J Periodontics Restorative Dent.* 2008;28(4):383-389.
6. Vercellotti T, De Paoli S, Nevins M. The piezoelectric bony window osteotomy and Linus membrane elevation: introduction of a new technique for simplification of the Linus augmentation procedure. *Int J Periodontics Restorative Dent.* 2001;21:561-567.
7. Pikos MA. Maxillary sinus membrane repair: update on technique for large and complete perforations. *Implant Dent.* 2008;17:24-31.
8. Soardi CM, Spinato S, Zaffe D, Wang HL. Atrophic maxillary floor augmentation by mineralized human bone allograft in sinuses of different size: an histologic and histomorphometric analysis. *Clin Oral Implants Res.* 2011;22:560-566.
9. Rosenlicht JL. Advancements in soft bone stability. *West Indian Dent J.* 2002;6(1):2-7.
10. Adell R, Lekholm U, Rockler B, Brånemark PI. A 15-year study of osseointegrated implants in the treatment of the edentulous jaw. *Int J Oral Surg.* 1981;10(6):387-416.
11. Soardi C, Zaffe D, Motroini A, Wang HL. Quantitative comparison of cone-beam computed tomography and microradiography in the evaluation of bone density after maxillary sinus augmentation. A preliminary study. *Clin Implant Dent Relat Res.* 2012;Nov 15. doi: 10.1111/cid.12016. [Epub ahead of print].
12. Bobyn JD, Stackpool GJ, Hacking SA, Tanzer M, Krygier JJ. Characteristics of bone ingrowth and interface mechanics of a new porous tantalum biomaterial. *J Bone Joint Surg Br.* 1999;81:907-914.
13. Wigfield C, Robertson J, Gill S, Nelson R. Clinical experience with porous tantalum cervical interbody implants in a prospective randomized controlled trial. *Br J Neurosurg.* 2003;17(5):418-425.
14. Unger AS, Lewis RJ, Gruen T. Evaluation of a porous tantalum uncemented acetabular cup in revision total hip arthroplasty. Clinical and radiological results of 60 hips. *J Arthroplasty.* 2005;20(8):1002-1009.